

*Amalgam, klasse I*

Asbjørn Jokstad  
 Institutt for klinisk odontologi  
 Universitetet i Oslo

---

---

---

---

---

---

---

---



*Okklusjonsflaten - Fissurer*

---

---

---


---

---

---

---

---



*Mulige funn i fissurer*

♦ Hypoplasi	♦ Utseende
♦ Misfarging	♦ Konsistens
♦ Tapt fylling	♦ Utstrekning
♦ <u>Karies</u>	♦ Penetrasjon og dybde

*Basert på:*

---

---

---

---

---

---

---

---



*Anatomi – snitt av fissur*



---

---

---

---

---

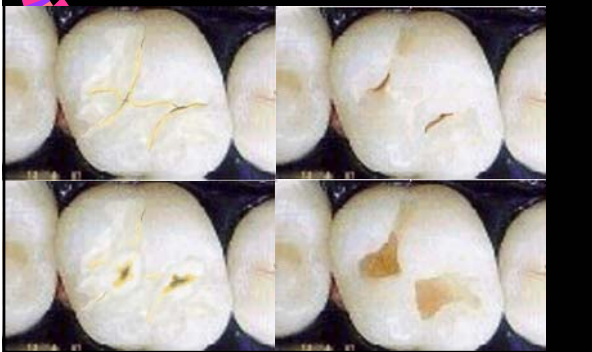
---

---

---



*Utvikling av en kavitet pga karies okklusalt*



---

---

---

---

---

---

---

---



***Fjern karies, men  
minst mulig  
tannsubstans!***

---

---

---

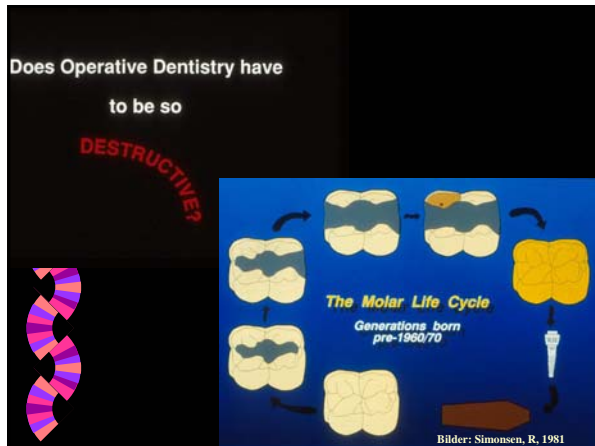
---

---

---

---

---




---

---

---

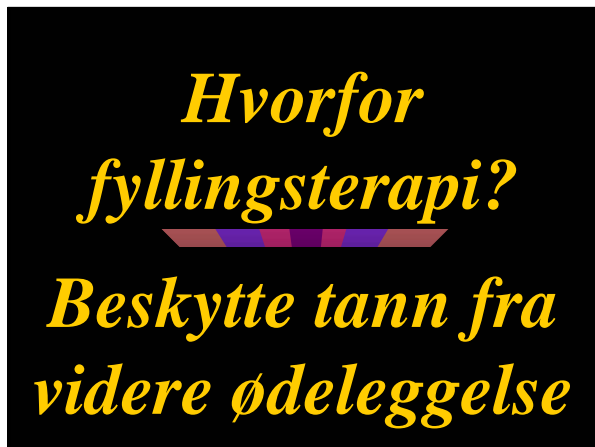---

---

---

---

---




---

---

---

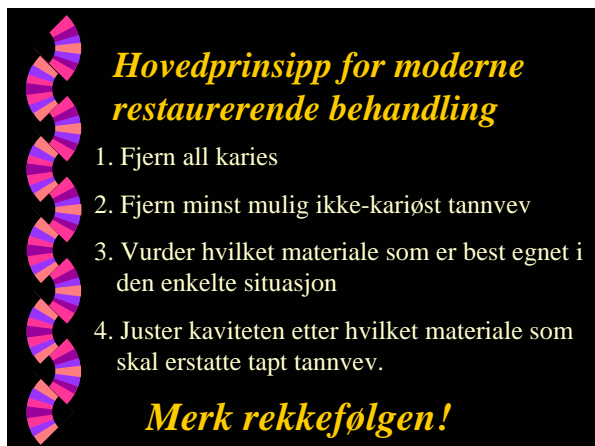---

---

---

---

---




---

---

---

---

---

---

---

---

### Alternative materialer

Små kaviteter	Store kaviteter
1. Plast ("resin")	1. Amalgam
2. Kompositt plast	2. Kompositt plast
3. Glassionomersement	3. Kompositt plast mod. m/ polyakrylsyre
4. Glassionomersement mod. m/ resin	
5. Kompositt plast mod. m/ polyakrylsyre	

---

---

---

---

---

---

---

---

### Amalgam til okklusale kaviteter

- Fordeler
  - Holdbarhet
  - Lav materialpris, enkel materialhåndtering
  - Enkel preparering,
- Ulemper
  - Vevsødeleggende
  - Estetikk
  - Amalgamfobi

---

---

---

---

---

---

---

---



Amalgamfyllinger i lateraltennene utgjør den største andelen av fyllinger i norske tenner

---

---

---

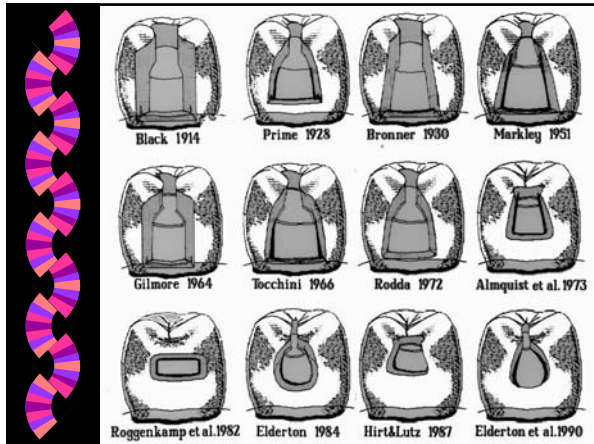---

---

---

---

---




---

---

---

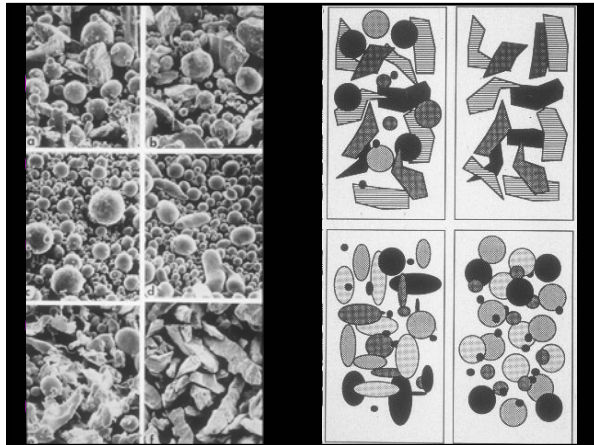
---

---

---

---

---




---

---

---

---

---

---

---

---

*Kavitetspreparering okklusalt*

**Fjern minst mulig tannvev!**

1. Åpne mistenkelige deler av fissurmønsteret med sylinderdiamant
2. Fjern kariøst dentin med rosenbor og ekskavator
3. Alle vinkler mellom kavitetsvegg og overflate > 70 grader

---

---

---

---

---

---

---

---

**Kavitetspreparering okklusalt**

**Fjern minst mulig tannvev!**

1. Åpne mistenkelige deler av fissurmønsteret med sylinderdiamant
2. Fjern kariøst dentin med rosenbør og ekskavator
3. Alle vinkler mellom kavitetsvegg og overflate > 70 grader

Marginal kantnedbrytning




---

---

---

---

---

---

---

---

Ny og gammel amalgamfylling




---

---

---

---

---

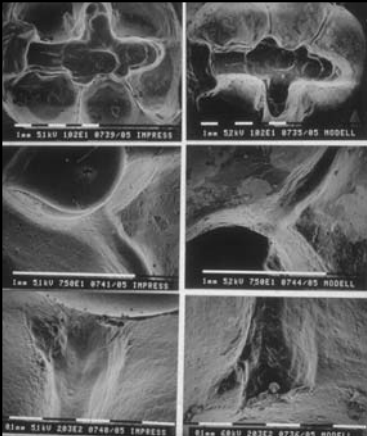
---

---

---

**Fjern minst mulig tannvev!**

1. Åpne mistenkelige deler av fissurmønsteret med sylinderdiamant
2. Fjern kariøst dentin med rosenbør og ekskavator
3. Alle vinkler mellom kavitetsvegg og overflate > 70 grader
4. Fissurer i tilknytning til kavitetsgrensen okklusalt skal utjevnes




---

---

---

---


---

---

---

---

**Kavitets-preparering**



**Fiern minst mulig tannvev!**

1. Åpne mistenkelige deler av fissurmønsteret med sylinderdiamant
2. Fjern kariøst dentin med rosenbor og ekskavator
3. Alle vinkler mellom kavitetsvegg og overflate > 70 grader
4. Fissurer i tilknytning til kavitetsgrensen okklusalt skal utjevnes
5. Unngå skarpe hjørner

---

---

---

---

---

---

---

---



**Frakturert amalgamfylling, med sekundærkaries**

1. Åpne mistenkelige deler av fissurmønsteret med sylinderdiamant
2. Fjern kariøst dentin med rosenbor og ekskavator
3. Alle vinkler mellom kavitetsvegg og overflate > 70 grader
4. Fissurer i tilknytning til kavitetsgrensen okklusalt skal utjevnes
5. Unngå skarpe hjørner
6. Dybde?

**Fiern minst mulig tannvev!**

---

---

---

---

---

---

---

---

**Viktig: Unngå salivakontaminasjon!**




---

---

---

---

---

---

---

---